

As Easy as Black & White CXR Interpretation



CHERYL HERRMANN, MD
FACR, FRCR, FRCR
Methodist Medical Center of Illinois, Peoria

cherrmann@frontier.com
www.cherylherrmann.com

1

1

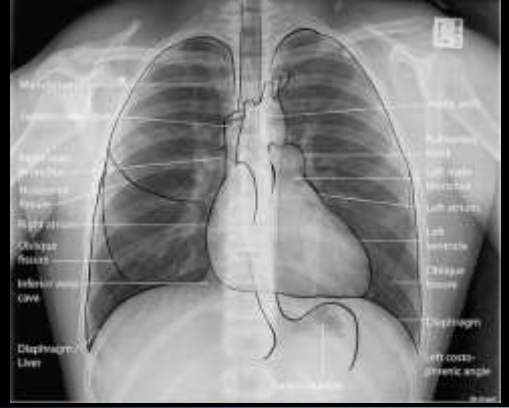
Chest x-ray anatomy



- 1 - Trachea
- 2 - Hila
- 3 - Lungs
- 4 - Diaphragm
- 5 - Heart
- 6 - Aortic knuckle
- 7 - Ribs
- 8 - Scapulae
- 9 - Breasts
- 10 - Bowel gas

2

2



3

3

Clinical Findings that show up **White**

- Pulmonary Edema
- Pneumonia
- Pleural Effusion
- Atelectasis
- ARDS
- Tumors
- Pericardial effusion/cardiac tamponade

4

4

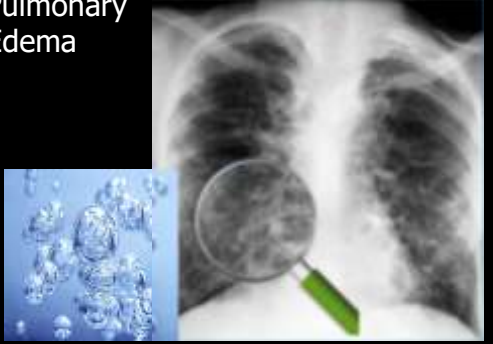
Pulmonary Edema

- Fluid in the pulmonary vasculature
- Will appear white on CXR
- Butterfly or batwing pattern
- Kerley B lines: thin linear pulmonary opacities caused for fluid or cellular infiltration into the interstitium of the lungs
- Treatment:
 - Diuretics

5

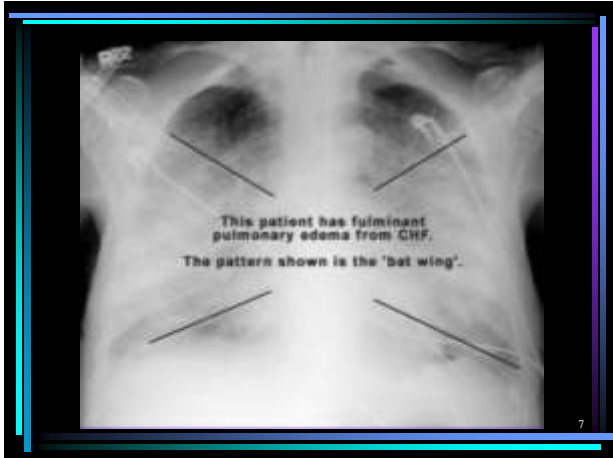5

Pulmonary Edema



6

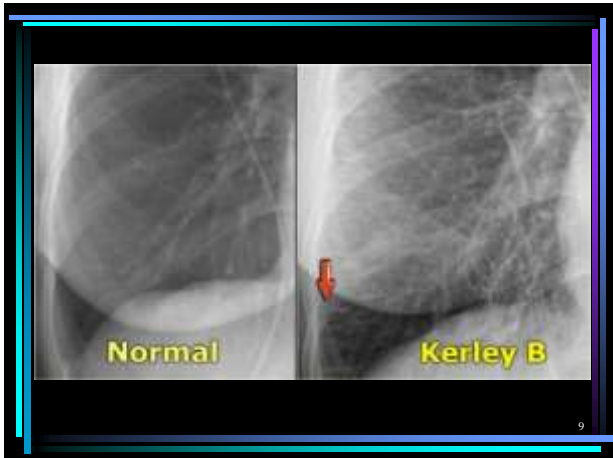6



7

- Kerley B Lines -- Horizontal lines < 2 cm long found in the lower zone periphery
- These lines are the thickened, edematous interlobular septa

8



9

Pneumonia

- A pattern of localized alveolar infiltrates
- May be localized to a single lobe or be more diffuse
- Will appear white on CXR
- Cause:
 - Infection
- Treatment
 - Antibiotics

10

Pneumonia

http://www.slideshare.net/mahayousif/utm_campaign=profiletracking&utm_medium=ssite&utm_source=sslideview

11

- Pneumonia
- Pulmonary Edema

12

Pleural Effusion

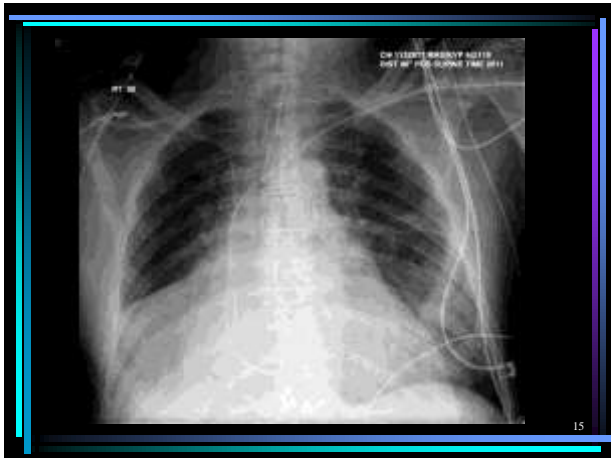
- Fluid in the pleural space
- At least 200 – 300 ml must be present in the pleural space to cause costophrenic blunting
- Treatment
 - Chest tube or thoracentesis to remove the fluid

13

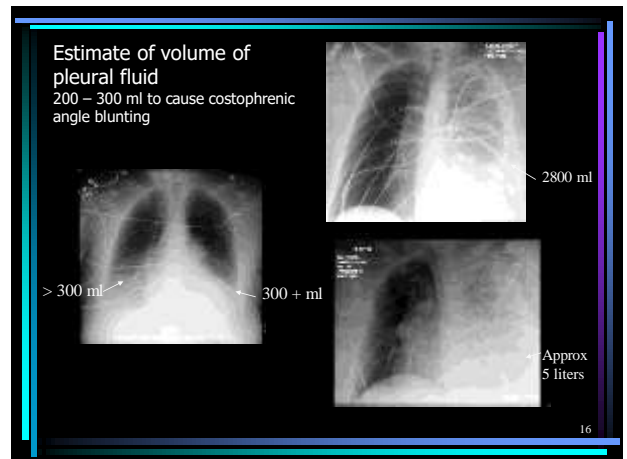
Pleural Effusion

- Fluid will be white or greyish in color
- Expect to see white in the pleural space
- Fluid Levels:
 - An upright CXR will ensure that fluid levels will drop to the bottom of the cavity.
 - Fluid levels taken on a patient lying will displace the fluid laterally over the cavity and will therefore not be detected as a distinct line

14



15

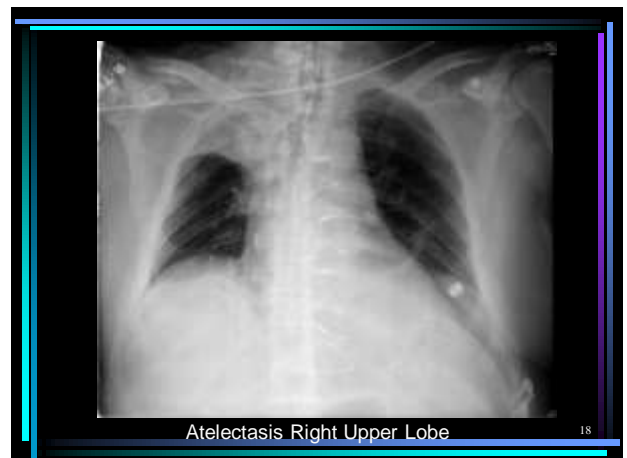

16

Atelectasis

- Collapsed or airless state of the alveoli (no oxygen in alveoli)
- Will appear white on the CXR
- Causes densities (white areas) of the lobes but usually not symmetrical changes in each lung field.
- To confirm atelectasis in lower lobe, a lateral CXR may be necessary

17



18

Atelectasis

- Causes:
 - Right mainstem intubation with ET tube
 - Secretions or mucous plugs
 - Hypoventilation of alveoli
- Treatment: Reexpand the alveoli
 - Ascertain proper ET tube placement
 - CPAP/BIPAP
 - Incentive spirometry
 - Bronchoscopy

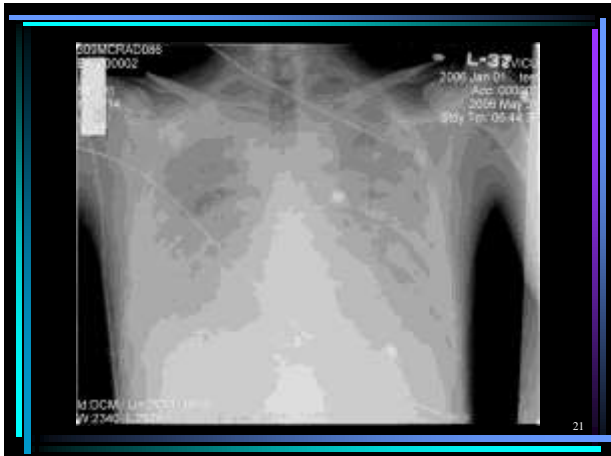19

ARDS

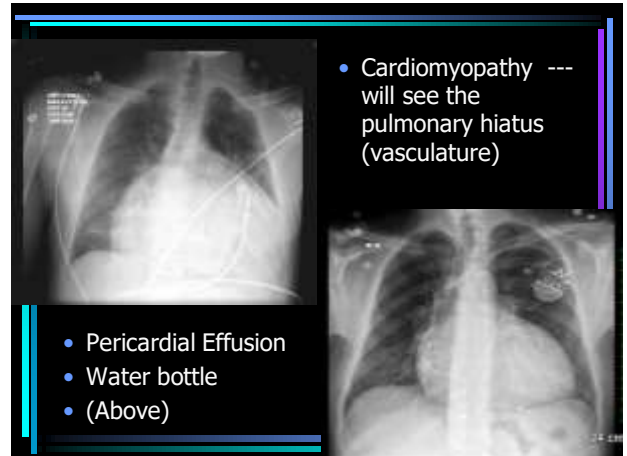
Acute Respiratory Distress Syndrome

- Acute alveolar insult causing pulmonary inflammation and small vessel injury
- Diffuse bilateral patchy infiltrates
- White infiltrates on CXR
- "Blizzard snowstorm"
- "Bilateral whiteout"

20



21

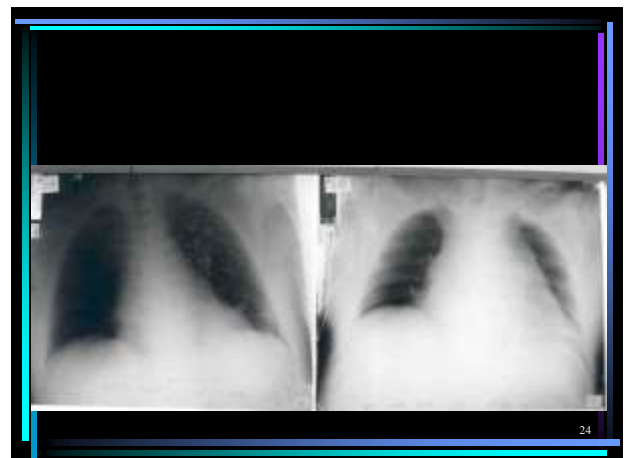


22

Cardiac Tamponade

- Fluid around the heart
- Appears white on the CXR
- Mediastinum gets wider and squares off
- Compare to older CXRs
- Causes
 - Chest trauma
 - Bleeding Post op Cardiac surgery

23



24

As Easy As Black

Clinical Findings that show up Black



25

Pneumothorax

- Air in the pleural space that inhibits complete lung expansion
- A thin, white line represents the displaced visceral pleura
- Small pneumothorax
 - Veil like line evident below the thoracic cage beyond which there are no lung markings.
- Large pneumothorax
 - Black area over entire lung field with no lung markings evident
- ICS may be farther apart on the side with pneumothorax

26

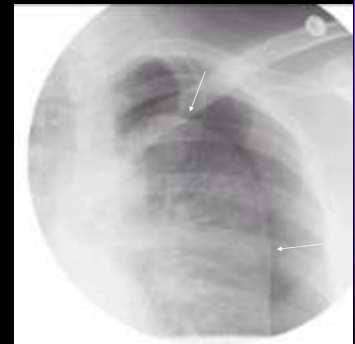
Pneumothorax

- Causes:
 - Anything that causes a tear in the lung: line insertion, rib fracture
- Treatment:
 - Chest tube insertion if greater than 10 – 15 %
 - If tension pneumothorax ---- it is a medical **EMERGENCY** and needs **immediate** needle decompression

27

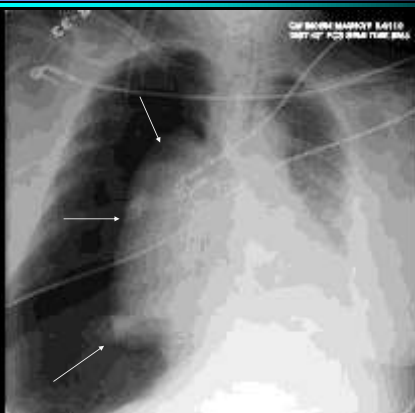27

- Left Pnemo under fluro



28

28



29

29

Power Point Handout available at www.cherylherrmann.com

References

- Connolly M A. Black, white, and shades of gray: Common Abnormalities in chest radiographs. *AACN Clinical Issues*. 2001;12(2):259-289.
- Lacey G, Morley S, et Berman L. *The Chest X-ray: A Survival Guide*. Philadelphia: Saunders/Elsevier.2008
- Siela D. Chest radiograph evaluation and interpretation. *Advanced Critical Care*. 2008;19(4):444-475.
- Siela D. Advanced Chest Imaging Interpretation of Acute Pulmonary Disorders. *AACN Advanced Critical Care*. 2015;25(4):365-386
- Huseby JS, Lecloux D. Radiologic Examination of the Chest. In: Woods SJ, Froelicher S, Motzer SA, Bridges E J, ed. *Cardiac Nursing*, 5th ed. Philadelphia: Lippincott Williams & Wilkens. 2005: 296-306.
- <http://radiologymasterclass.co.uk/tutorials/tutorials.html>
- www.medmastery.com

30

30